



AUSTRALIAN DENTAL
ASSOCIATION

Ankyloglossia and Oral Frena Consensus Statement

Acknowledgments

The Australian Dental Association, in association with an expert multidisciplinary panel of health professionals has developed the *Ankyloglossia and Oral Frena Consensus Statement* to provide evidence-based recommendations to guide best practice in caring for individuals with short, tight labial and lingual frena and ankyloglossia. Working group members are acknowledged below.

Expert working group members

Chair	Dr Mihiri Silva (Paediatric Dentist) BDSc, MDSc, DCD (Paediatric Dentistry), PhD
Australasian Academy of Paediatric Dentistry (AAPD)	Dr Kareen Mekertichian (Paediatric Dentist) BDS, MDSc, FRACDS, MRACDS (Paed Dent), FICD, FPFA
Australian Chiropractors Association (ACA)	Dr Russell Mottram (Chiropractor) B.App.Sc (Chiropractic)
Australian College of Midwives (ACM)	Ms Lois Wattis (Clinical Midwife and IBCLC) BNurs, PGradDipMidwifery, FACM, IBCLC
Australian College of Midwives (ACM)	Ms Michelle Simmons (Clinical Midwife Consultant, Westmead) MNurs, IBCLC
Australian Dental Association (ADA)	Prof Laurence Walsh (Specialist in Special Needs Dentistry) BDSc, PhD, DDSc, GCEd, FRACDS, FFOP (RCPA)
Australian Dental Association (ADA)	Dr Philippa Sawyer (Paediatric Dentist) BDS (USyd), MA (Sports Studies) (UTS), GradCertPedDent (NYU) PGCertHEd (MQU), Master of Early Childhood (MQU), FICD, FAAPD, FIADT Diplomate, American Board of Pediatric Dentistry
Australian Dental Association (ADA) Deputy CEO & Policy General Manager	Ms Eithne Irving RN, Grad Dip Neuroscience, MBA
Australian Dental Association (ADA) Oral Health Promoter	Dr Mikaela Chinotti (Dentist) BDS, MPH
Australian Dental & Oral Health Therapists' Association (ADOHTA)	Ms Nicole Stormon (Oral Health Therapist) BOH, AFHEA
Australian and New Zealand Association of Oral and Maxillofacial Surgeons (ANZAOMS)	A/Prof David Sherring (Oral and Maxillofacial Surgeon) MBBS, BDS, DCLinDent, FRACDS (OMS) President ANZAOMS (2017-2019)
Lactation Consultants of Australia & New Zealand (LCANZ)	Ms Heather Gale (IBCLC, Registered Nurse and Midwife) IBCLC/RN/RM/Post grad. Dip Nurse Ed./M. Nursing
Osteopathy Australia (OA)	Dr Julie Fendall (Osteopath) DO MStSc (Paeds)
Royal Australasian College of Dental Surgeons (RACDS)	Dr Kelly Oliver (Paediatric Dentist) BDSc, DCLinDent, FRACDS (Paeds)
Speech Pathology Australia (SPA)	Ms Emma Necus (Speech Pathologist) Speech Pathologist (MSc/Bsc), IBCLC Dr John Sinn (Neonatologist) MBBS(Syd), DCH, Dip Paed, MMed (C Epi), FRACP (Paed)

Executive Summary

The *Ankyloglossia and Oral Frena Consensus Statement* provides a multi-disciplinary, evidence-based consensus regarding the diagnosis and management of short, tight labial and lingual frena and ankyloglossia.

Working Group

The consensus statement was formed by a multidisciplinary working group of health professionals representing ten organisations and associations and is intended to guide best practice. It is based on existing evidence, including a systematic Cochrane Review, an updated broader literature review and the expert opinion of the working group.

Health Problems

Ankyloglossia can cause some individuals to experience functional limitations, such as difficulty breastfeeding. Further research is needed regarding other reported adverse health outcomes, such as problems with speech, malocclusion, lingual gingival recession and obstructive sleep apnoea as evidence of a consistent causative relationship is lacking. No evidence exists to support buccal or labial frena causing problems with feeding or speech.

Diagnosis

The anatomical appearance of oral frena can demonstrate considerable variability without functional issues. Therefore, diagnosis of ankyloglossia should not be based solely on anatomic appearance. The key pre-requisites for a diagnosis are:

1. Thorough case history.
2. Objective functional assessment of tongue function using a diagnostic system.
3. Complete assessment of functional issues impacted by the suspected ankyloglossia by a qualified professional.

Management

Contemporary management of ankyloglossia includes a range of treatments and requires inter-disciplinary care by multiple health professionals. Non-surgical management strategies can be effective first-line therapies for management of functional limitations associated with ankyloglossia.

Surgical management should be considered only after non-surgical management has failed to address the functional issue that led to the diagnosis. Treating clinicians must understand surgical techniques, possess the ability to identify and manage complications as well as have access to and training in resuscitation equipment appropriate to the age of patients treated.

Appropriate analgesia and anaesthetic use should be considered for individuals of all ages.

Final remarks

The statement highlights the importance of multi-disciplinary care and communication between treating health professionals. Further research is required to clarify many issues relating to ankyloglossia, particularly the effects of surgical management on improving functional limitations and the long-term effects of surgical intervention on neonates.

Part 1

The purpose of this *Ankyloglossia and Oral Frena Consensus Statement* is to provide a multi-disciplinary, evidence-based consensus regarding the diagnosis and management of short, tight labial and lingual frena and ankyloglossia to guide best practice.

Background

The lingual frenum refers to the mucous membrane that connects the ventral surface of the tongue to the floor of the mouth. Ankyloglossia, commonly referred to as 'tongue-tie,' describes restricted movement of the tongue causing functional limitations, accompanied by a visually restricted lingual frenum.

Ankyloglossia is a congenital anomaly that has been reported in neonates, infants, children and adults. It has been suggested to be linked with a range of health issues, including breastfeeding, speech and dental problems, such as malocclusion. Contemporary management of these problems includes a range of treatments and health professionals.

In recent years, there has been a large increase in the referral and surgical management of newborns, infants and children with ankyloglossia. A 420% increase in frenotomy rates, as derived from Medicare data, was reported in Australia over the last decade.¹ Surgical management has also reportedly increased in Canada² and North America.³

Despite considerably differing views on the topic, there are currently no Australian guidelines that inform the diagnosis and management of ankyloglossia. Therefore, a working group of relevant key bodies was established to create this consensus statement to provide objective and evidence-based advice for the assessment and management of ankyloglossia and other intra-oral frena in neonates, infants, children and adults. This statement covers the definition, diagnosis, associated health issues and management of ankyloglossia and other oral frena, and complications and post-operative care following surgical management.

This consensus statement strongly and wholly supports the World Health Organization (WHO)'s recommendations for infant and young child feeding, including that mothers breastfeed infants for their first six months of life to achieve optimal growth, development and health. ⁴

Consensus statement development

To form the multidisciplinary working group to develop the *Ankyloglossia and Oral Frena Consensus Statement*, the Australian Dental Association (ADA) invited relevant health associations and organisations to partake by nominating a representative. The statement was developed through meetings (one face-to-face and one teleconference) and additional email correspondence between working group members over a period of six months..

The final panel included 14 health professionals representing the following associations or organisations:

- Australasian Academy of Paediatric Dentistry (AAPD);
- Australian Chiropractors Association (ACA);
- Australian College of Midwives (ACM);
- Australian Dental Association (ADA);
- Australian Dental & Oral Health Therapists' Association (ADOHTA);
- Australian and New Zealand Association of Oral and Maxillofacial Surgeons (ANZAOMS);
- Lactation Consultants Australia and New Zealand (LCANZ);
- Osteopathy Australia (OA);
- Royal Australasian College of Dental Surgeons (RACDS);
- Speech Pathology Australia (SPA).

Prior to meeting, the group was provided with Terms of Reference, proposed points for consensus, rapid reviews of available literature and current Australian and international guidelines, policies and position statements, as collated by the ADA's Oral Health Promoter. Group members were encouraged to suggest additional pre-reading that was not otherwise included in the rapid review. The proposed points for consensus included:

- DEFINITION, of terms including lingual frenum, ankyloglossia and 'posterior' tongue-tie
- DIAGNOSIS, including the health professionals best placed to recognise ankyloglossia and the preferred diagnostic tools
- ASSOCIATED HEALTH ISSUES, including breastfeeding problems, speech and articulation problems, malocclusion, gingival recession, gastroesophageal reflux disease (GORD), obstructive sleep apnoea (OSA), difficulty transitioning to solid food or muscular tension
- MANAGEMENT, including treatment setting and practitioner qualifications
- SURGICAL INTERVENTION, including indications and recommended management pathway prior to surgical intervention
- ARMENTARIUM, including recommended instrumentation for division of oral frena
- INFORMED CONSENT, including risks to discuss when gaining informed consent
- POST-OPERATIVE CARE, including wound care and pain management
- COMPLICATIONS associated with treatment

The first group meeting was held face-to-face at the ADA on July 17, 2019. It was chaired by Dr Mihiri Silva, paediatric dentist, and supported by Dr Mikaela Chinotti, dentist and ADA Oral Health Promoter. The meeting was audio recorded and transcribed.

The working group was divided into four sub-groups and allocated proposed points for consensus, as relevant to their discipline, for discussion. Within groups, members explored current standards of care, summarised findings of relevant publications, shared their expert experience and identified areas for further investigation. Each group developed a preliminary consensus regarding the assigned points of discussion, which was presented to the working group for debate between all members. Consensus was considered to be achieved when assent was obtained.

Based on the preliminary consensus developed at the face-to-face meeting on July 17, 2019, a written draft was provided to the working group for comment prior to a teleconference meeting for further discussion to refine the draft. The teleconference was audio recorded and transcribed. A second draft was disseminated to the working group for comment.

The final Ankyloglossia and Oral Frena Consensus Statement draft was provided to the working group prior to dissemination to the invited and additional health organisations and associations for the option to become a signatory.

An electronic database search to review the literature was conducted and the evidence appraised. Details are provided in Part Two and Appendices A and B.

All nominees declared no conflicts of interest. No external funding was provided to the ADA for the development of this statement.

Glossary

Frenotomy/frenulotomy – division of a frenum without suture or revision of the remaining tissues⁵

Frenuloplasty – division of a frenum and closure of the mucosa with sutures⁵

Frenectomy/frenulectomy – excision of a frenum⁵

Surgical management – surgical intervention of a frenum using techniques including frenotomy/frenulotomy, frenuloplasty or frenectomy/frenulectomy

Cold steel – term describing surgical procedures performed using a metal blade instrument, i.e. scalpel, scissors

Fascia - a sheath, a sheet or any number of dissectible aggregations of connective tissue that forms beneath the skin to attach, enclose or separate muscles and other internal organs.⁶

Neonates – babies aged less than 28 days

Infants – babies aged 1–12 months

Statement of Consensus

Definition

Lingual Frenum - Lingual frenum is the name given to describe the anatomical structure which is *“a dynamic structure formed by a central fold of fascia that spans the floor of mouth and together with the overlying oral mucosa it forms the “roof” of the sublingual space...the fascia connects around the anterior and lateral ventral surfaces of the tongue, to stabilize tongue position while allowing freedom of movement.”*⁷

Ankyloglossia - Ankyloglossia refers to the restricted movement of the tongue causing functional limitations, accompanied by a visually restricted lingual frenum.

Posterior Tongue Tie - The term ‘posterior’ tongue tie was introduced in 2004 through an opinion piece published in the *American Academy of Pediatrics* newsletter by Coryllos, Genna and Salloum,⁸ classifying the distance of the tongue tip to the leading edge of the frenum.

There is a lack of evidence from dissection studies to support such an entity.⁷ Use of this term can result in a normal lingual frenum being classified as abnormal. The term ‘posterior’ tongue tie should not be used as a medical diagnosis.

Diagnosis

Diagnosis of ankyloglossia should not be based solely on anatomic appearance. The presence of a functional limitation, such as difficulty in breastfeeding, and an anatomically restricted lingual frenum should both be present for a diagnosis of ankyloglossia. In the absence of a functional limitation, the lingual frenum should be considered functionally normal.

Many adults and children will not experience functional limitations associated with a short, tight lingual frenum. Assessment of function should be modified according to age and life-stage, such as breastfeeding, starting solid foods, speech and appearance of both the primary and secondary dentition. In infancy and early childhood, appropriately-trained health professionals with an understanding of neonatal feeding and the biomechanics of nutritive and non-nutritive sucking such as International Board Certified Lactation Consultants (IBCLCs), midwives, child health nurses and/or speech pathologists, are best placed to recognise ankyloglossia.

All current diagnostic systems have inherent limitations. Some systems describe frenum appearance but provide no diagnostic value. Many remain unvalidated but have been shown to influence clinical care. Diagnostic systems that include assessment of both tongue function and appearance, such as Martinelli⁹ and Hazelbaker¹⁰ are preferable over those that classify ankyloglossia purely on anatomic appearance.

A diagnosis of ankyloglossia may be considered after the following steps are completed:

1. A thorough case history has been taken.
2. Objective functional assessment of tongue function has been completed (using a diagnostic system, such as Martinelli⁹ or Hazelbaker¹⁰).
3. A complete assessment of factors impacted by the suspected ankyloglossia by a qualified professional (e.g. breastfeeding observation by an IBCLC).

Associated Health Issues

Breastfeeding issues can be associated with ankyloglossia.¹¹

A minority of children may develop speech problems as a result of ankyloglossia. No available evidence demonstrates causative association between ankyloglossia and speech articulation problems, including a delay in, or lack of speech development,¹² particularly in children who have not had feeding issues. Additionally, no method exists for predicting which infants may experience speech difficulties.

There is no evidence to suggest that buccal or labial frena can lead to problems with feeding or speech.¹³

Oral problems, such as malocclusion, may arise in a minority of individuals with a prominent lingual or labial frenum. Malocclusion, gingival recession and dental caries cannot be predicted based on the anatomic appearance of the frenum in infancy or early childhood.

There is insufficient evidence to definitively conclude that ankyloglossia causes other health problems, including sleep disordered breathing, gastroesophageal reflux disease (GORD), colic or difficulty transitioning to solid foods.

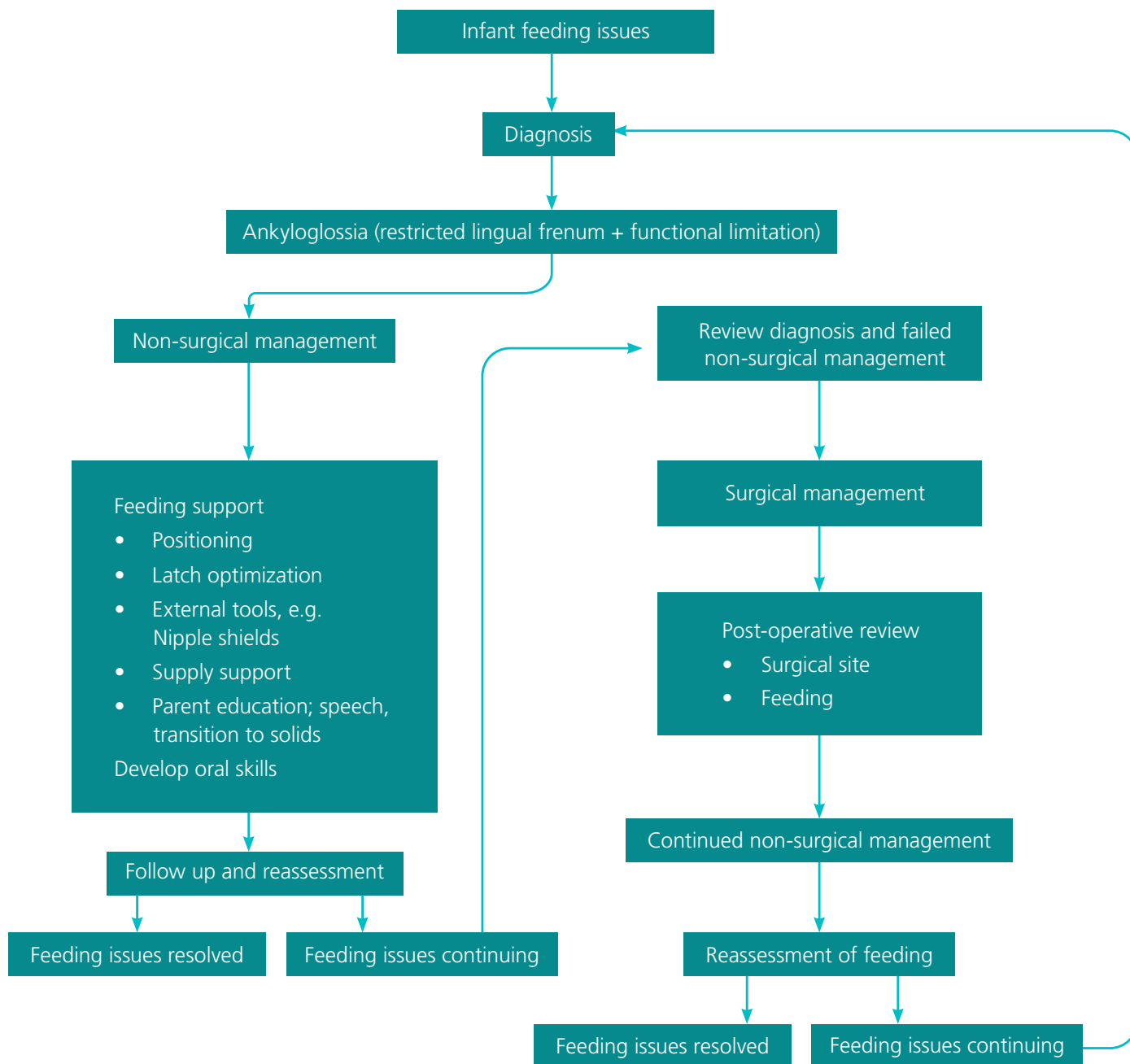
Non-surgical management

There is evidence that non-surgical management strategies can be an effective first-line therapy for the management of functional limitations related to ankyloglossia.¹⁴

Non-surgical strategies for management of ankyloglossia include treatment to optimise neonatal and infant feeding and nutrition and growth, with appropriately-qualified health professionals, such as IBCLCs, midwives, child health nurses and/or speech pathologists.

Management can include advice on positioning, latch optimisation, feed frequency, supporting mothers to maintain milk supply, and the use of external tools such as nipple shields or supplementary nursing systems.

Figure 1. Suggested management pathway for infants diagnosed with ankyloglossia.



Surgical Management

Surgical management of the lingual frenum may be indicated after:

1. Diagnosis of ankyloglossia by an appropriately-trained health professional using appropriate diagnostic assessments;
2. Failure of non-surgical management; and
3. Full informed consent is obtained.

Surgical management should not take place without the presence of a well-defined structural problem, which is causing functional issues. Likewise, surgical management should not be undertaken based on speculation about future problems despite lack of current problems.

There is insufficient evidence to support the surgical release of the labial or buccal frena in infants to assist with breastfeeding difficulties, speech outcomes, or orthodontic issues including midline diastema closure.¹⁵

As part of orthodontic management, a minority of older children and adults with intra-oral frena associated with malocclusion, may benefit from timely surgical release.

Following receipt of a referral, health professionals who undertake surgical management are obliged to reassess the need for surgical management and review the already completed non-surgical care. Treating health professionals should obtain written consent from patients or parents/guardians. Discussion should include appropriate disclosure of potential complications of the surgery.

Surgical management should only be undertaken by appropriately trained health professionals working in an appropriate clinical setting that can manage possible complications. Treating clinicians must understand surgical techniques and possess the ability to identify and manage complications appropriate to the age of the patient, including access to specialist care. Treating health professionals should have training in and access to resuscitation equipment appropriate to the age of the patients treated. Treating healthcare facilities should have well documented and implemented practice protocols for managing complications associated with surgical intervention.

If a patient, parent and/or health professional performing a procedure identify a complication (including incomplete division or apparent reattachment due to scar formation), then specialist referral, such as to an ear, nose and throat (ENT) surgeon, paediatrician, paediatric surgeon, paediatric plastic surgeon, paediatric dentist or oral maxillofacial surgeon is recommended.

Neonates and Infants

Thorough pre-operative assessment of possible contraindications for surgery is mandatory. Contraindications for surgical intervention may include orofacial malformations such as cleft palate, Pierre Robin Sequence, bleeding disorders, neuromuscular conditions and vitamin k deficiency. Routine post-birth vitamin k administration needs

to be confirmed in neonates and infants undergoing surgical management.

If surgical intervention is deemed necessary, the age of the patient influences the surgical approach. Cold steel frenotomy using scissors is recommended in neonates. Laser or cold steel may be appropriate in infants. Risks associated with the use of laser surgery include eye exposure, inhalation of plume and aspiration of coolant spray, plume and/or blood.

Age-appropriate analgesia for pain control or management should be instituted. Management of intra-operative pain is an important consideration as neonates and infants can experience pain from cold steel or laser surgery.

Neonates receiving surgical management should undergo treatment in an established healthcare facility or tertiary setting with access to neonatal resuscitation equipment and the ability to manage acute airway and/or bleeding complications.

Children and Adults

Surgical management in adults should be considered elective treatment.

The use of cold steel or laser surgery may be suitable in children and adults, with consideration of appropriate anaesthesia and analgesia.

Complications

The surgical management of ankyloglossia carries the risk of both acute and chronic complications.

Acute complications can include deep ulceration, bleeding, haematoma, airway compromise, swelling, restricted tongue movement and iatrogenic injury.

Chronic complications can include 'recurrent ankyloglossia' due to scar tissue formation, sub-mandibular salivary gland duct injury, oral aversion, ranula, tongue paraesthesia and infection.

Although it may be regarded a simple procedure to perform, complications can be potentially life-threatening. Reports exist of large volume blood loss causing hypovolemic shock in neonates;^{16,17} a condition that can present initially with subtle symptoms¹⁸ but rapidly progress in neonates.

Following surgical management, there is no guaranteed improvement of the functional limitation for which surgery was sought. Patient issues may worsen, or new issues may develop post-operatively.

Table 1. Reported complications following surgical management of lingual and labial frena

Article	Study Design and Participants (N)	Complications
Hale et al. 2020. ¹⁷	Observational, cohort study N = 16	<ul style="list-style-type: none"> • Poor feeding • Apnoea or other breathing difficulty • Pain • Bleeding • Weight loss • Pallor/Anaemia • Excess scarring • Delayed diagnosis of alternative underlying medical condition
Dixon B et al. 2018. ¹⁹	Observational, cohort study N = 367	<ul style="list-style-type: none"> • Severe bleeding • Submandibular oedema • Oral aversion • Division of the submandibular salivary ducts
Suter V, Bornstein M. 2009. ²⁰	Systematic review	<ul style="list-style-type: none"> • Excessive bleeding • Recurrent ankyloglossia due to excessive scarring • Upper airway collapse • Functional disturbances; lingual dysfunction and deglutitory anomalies
Zaghi S et al. 2019. ²¹	Observational, cohort study N = 420	<ul style="list-style-type: none"> • Lingual paraesthesia • Salivary gland inflammation and swelling • Increased salivation and jetting of saliva • Sleep-disordered breathing
Varadan M et al. 2019. ²²	Critical review	<ul style="list-style-type: none"> • Excessive bleeding or haemorrhage • Retention cyst or ranula • Sublingual haematoma • Reattachment/recurrence of frenal attachment • New speech disorder or worsened existing speech disorder • Paraesthesia of the tongue and neighbouring soft tissues
Tracy LF et al. 2017. ¹⁶	Case report N = 2	<ul style="list-style-type: none"> • Large volume blood loss causing hypovolemic shock. Case 1 required cardiopulmonary resuscitation, while Case 2 underwent emergent operative treatment to control bleeding. Both cases required blood transfusions.
Maciag M et al. 2016. ²³	Case report N = 1	<ul style="list-style-type: none"> • Ludwig's angina
Genther DJ et al. 2015. ²⁴	Case report N = 1	<ul style="list-style-type: none"> • Prominent glossoptosis in supine position <ul style="list-style-type: none"> - Near complete obstruction of the pharyngeal airway - Nasogastric tube and gastrostomy tube for feeding
Isaiah A, Pereira KD. 2013. ²⁵	Case report N = 1	<ul style="list-style-type: none"> • Infected hematoma
Opara PI et al. 2012. ²⁶	Case report N = 2	<ul style="list-style-type: none"> • Large volume blood loss

Post-operative care

Post-operative care to minimise complications and support patients and families to overcome functional problems that initiated the surgical intervention is essential. Care should be appropriate to the procedure performed as well as the diagnosis and functional limitation originally established.

Administration of pharmacological analgesics to neonates should be provided in consultation with a neonatologist or paediatrician. Non-pharmacological analgesic strategies can include skin-to-skin contact, sucrose with or without a pacifier and breastfeeding or the provision of expressed breastmilk or colostrum.

Post-operative breastfeeding support for the mother-infant dyad is essential. All neonates and infants who undergo surgical management of ankyloglossia due to breastfeeding difficulties should receive breastfeeding support from an appropriately qualified health professional.

Contemporary post-operative care increasingly includes stretching of the soft tissue wound following division of a frenum to prevent 'reattachment' of wound margins. There is no scientific evidence to support these stretches, which are commonly referred to as 'active wound management' stretches. Stretching of surgical wounds is not recommended as it prolongs healing time and increases risk of scarring and infection.²⁷ The lack of a scientific reason for carrying out these stretches is a medico-legal risk for clinicians who recommend and use this approach.

Training

No training courses exist that allows any member of a health profession to register as a specialist or 'expert' in the treatment of ankyloglossia. Individuals must not advertise themselves as registered specialists in ankyloglossia or tongue tie management specifically.

The *Health Practitioner Regulation National Law Act 2009* Section 115 (1) states that "A person must not knowingly or recklessly take or use - (c) a specialist title for a recognised specialty unless the person is registered under this Law in the specialty."

Future Directions

Further research, preferably through randomised controlled trials (RCT)'s or high quality observational studies employing objective outcomes, is required. Further understanding of many aspects is required, particularly the effects of surgical management on improving functional limitations and the long-term effects of surgical intervention on neonates, as memories of pain may be recorded biologically, and consequently alter brain development and subsequent behaviour.²⁸

Part Two

Supporting Evidence

Search Strategy

An electronic search was conducted in August 2019 using the Medline (Ovid) and Embase Databases.

The search strategy was developed with the assistance of an experienced librarian (Tables 2 and 3). In addition, hand searching of the reference lists of selected studies and a number of paediatric journals was performed. Unpublished studies were sought by contacting experts in the field and by searching the ProQuest Dissertations and Theses global database.

Table 2: Medline (Ovid) search terms:

1. Ankyloglossia/
2. (ankylogloss* or tongue-tie* or tonguetie*).tw,kf.
3. Lingual Frenum/ab, su or Labial Frenum/ab, su
4. (frenulum or frenum or frena).tw,kf. and ((abnormal* or surger* or surgical* or operat* or repair).tw,kf,hw. or (su or ab).fs.)
5. (Frenulectom* or Frenectom* or frenotom*).tw,kf.
6. treatment outcome/
7. exp Speech Disorders/
8. Speech Intelligibility/
9. (speech or dental or caries or malocclusion* or mal-occlusion*).tw,kf,hw.
10. Breast Feeding/
11. (breastfeeding or breast-feeding).tw,kf.
12. malocclusion/ or dental occlusion, traumatic/ or open bite/ or dental caries/
13. (1 or 2 or 3 or 4 or 5) and (6 or 7 or 8 or 9 or 10 or 11 or 12)
14. limit 13 to case reports
15. 13 not 14

Table 3: Embase search terms:

1. ankyloglossia/
2. (ankylogloss* or tongue-tie* or tonguetie*).tw,kw,dq.
3. tongue frenulum/ or labial frenum/
4. (frenulum or frenum or frena).tw,kw,dq. and ((abnormal* or surger* or surgical* or operat* or repair).tw,kw,dq,hw. or su.fs.)
5. (Frenulectom* or Frenectom* or frenotom*).tw,kw,dq.
6. frenotomy.hw.
7. oral surgery/
8. treatment outcome/
9. exp speech disorder/
10. speech intelligibility/
11. (speech or dental or caries or malocclusion* or mal-occlusion*).tw,kw,dq,hw.
12. exp infant feeding/
13. (breastfeeding or breast-feeding).tw,kw,dq.
14. feeding difficulty/
15. malocclusion/ or exp tooth occlusion/ or dental caries/
16. (1 or 2 or 3 or 4 or 5 or 6) and (8 or 9 or 10 or 11 or 12 or 13 or 14 or 15)
17. (1 or 2) and 7
18. 16 or 17

Can non-surgical management be effective in improving breastfeeding?

Evidence from two prospective cohort studies demonstrates that early feeding support can reduce the need for surgical intervention in cohorts of babies referred for frenotomy.¹⁹ A summary of the findings from these studies can be found in Appendix A.

Can surgical management be effective in improving breastfeeding?

A Cochrane review conducted in 2017 reported frenotomy to not consistently improve infant feeding and to be more likely to improve (short term) nipple pain with long term follow-up data limited due to high contamination of control groups.²⁹ The review advised that few randomised controlled studies have reported improvements in breastfeeding effectiveness after frenotomy,²⁹ however, all have significant limitations. No new systematic reviews or RCTs have been released following the 2017 Cochrane review. A summary of findings can be found in Appendix A.

Does a short, tight lingual frenum influence speech problems?

The 2013 systematic review by Webb, Hao and Hong reported no causative association between ankyloglossia and speech articulation problems.¹² Evidence released since has not demonstrated otherwise.^{30,31} There is no evidence to recommend division for all individuals with a short, tight lingual frenum.^{30,32,33} A summary of the findings from these studies can be found in Appendix B.

Is ankyloglossia related to the development of malocclusion?

A systematic (critical) review of the impact of ankyloglossia on malocclusion evaluated four case reports/series that found *limited evidence that tongue-tie represents a (co)-factor in the development of malocclusions*.²⁰

Further research in the form of cohort and clinical trials is required to determine whether a clear relationship exists.

Does ankyloglossia cause dental caries?

One review of the literature³⁴ investigated the notion that short, tight lingual or labial frena cause increased risk of early childhood caries (ECC). It reported *no high-quality evidence to support a correlation between ankyloglossia or maxillary lip-tie and an increased risk of early childhood caries*.³⁴ No studies were found that reported caries incidence for children or adults with short, tight lingual or labial frena.

Confounding factors such as regular consumption of cariogenic foods and drinks and/or inadequate oral hygiene practices should be considered in association with caries development.

Does ankyloglossia cause lingual gingival recession?

The notion that lingual gingival recession may be due to high frenal attachment is a subject of controversy in the literature. Further research is required to determine whether a clear relationship exists.²⁰

Does ankyloglossia cause obstructive sleep apnoea

(OSA)?

Three observational studies^{35,36,37} evaluating short lingual frenulum and obstructive sleep apnoea in children were identified. All studies reported a short lingual frenulum being related to obstructive sleep apnoea in children; however, none demonstrated a definitive cause and effect relationship.

Does ankyloglossia cause gastroesophageal reflux

disease (GORD)?

The group supports Douglas's 2017³⁸ review of the relationship between ankyloglossia and GORD. No gold standard diagnostic tool exists for the diagnosis of GORD in neonates or infants.^{39,40} Evidence^{41,42,43} associating ankyloglossia with GORD in neonates or infants is subjective and anecdotal. It does not demonstrate causation and is not strong enough to provide a basis for decisions to surgically treat ankyloglossia.

Does musculoskeletal therapy, including chiropractic or osteopathic care, assist breastfeeding practices in infants with ankyloglossia?

Few studies support manual interventions to correct infant musculoskeletal dysfunctions linked to suboptimal breastfeeding;^{44,45,46} however, there is no evidence linking musculoskeletal therapy to ankyloglossia management alone.

Appendix A. Summary of studies investigating the impact of surgical and non-surgical management of intra-oral frena on breastfeeding.

Study	Design	Participants (N)	Intervention	Outcomes	Risk of Bias
Colaway 2019 ¹⁴	Observational, cohort	N = 115 infants	Individual breastfeeding evaluation and support	Reduced need for surgical intervention - Breast feeding established with non-surgical intervention for 62.6% of participants initially referred for surgical intervention	<ul style="list-style-type: none"> Poorly defined control group Inconsistent follow-up
Dixon 2018 ¹⁹	Observational, cohort	N = 367 infants	Community level education and breastfeeding support	Frenotomy rate reduced from 11.3% in 2015 to 3.5% in mid-2017	<ul style="list-style-type: none"> Non-validated questionnaire
Schlatter 2019 ¹¹	Observational, cohort	N = 776 mother-infant dyads	Frenotomy; method not advised	LATCH score improved from 6.9 to 9.5* following frenotomy	<ul style="list-style-type: none"> Selective outcome reporting Control group included but results not reported
Ramoser 2019 ⁴⁷	Observational, case control	N = 329 patients (295 infants and 34 children)	Scissors frenotomy	106/126 short-term and 114/138 long-term improvements	<ul style="list-style-type: none"> Selective outcome reporting Potential recall bias Improvement outcomes do not distinguish breastfeeding from speech/language Unblinded No control group Parental reporting; cannot discount placebo effect

*Mann-Whitney U test
N = number of participants

Appendix B. Summary of studies investigating impact of intra-oral frena on speech problems

Study	Design	Participants (N)	Intervention	Outcomes	Risk of Bias
Webb 2013 ¹²	Systematic review	4 observational studies	Subjects with ankyloglossia underwent tongue-tie division	No causative association between ankyloglossia and speech articulation	<ul style="list-style-type: none"> • Non-randomised - selection bias • Non-blinded • Lack of comparison or control group • Small sample sizes • Lack of statistical analysis of outcomes • Results based on parental recall – potential recall bias
Walls 2014 ³¹	Observational, case-control	N = 104 children	Frenotomy within the first month of life	Infants who underwent frenotomy demonstrated improved speech outcomes (Likert 4.52) compared to those who did not undergo frenotomy (Likert 3.60)	<ul style="list-style-type: none"> • Non-randomised – selection bias • Subjective outcomes • Ankyloglossia based on anatomy only • No professional evaluation of survey • Small sample size • Results based on parental recall – potential recall bias • No baseline data to determine improvement • Reason for frenotomies not advised
Daggumati 2019 ³²	Observational,	N = 188 children	Frenulectomy	Children with moderate and moderate-to-severe speech and language impairment attained better outcomes (100%) post-frenotomy compared to mild and mild-to-moderate impaired children (82%); P = 0.015	<ul style="list-style-type: none"> • Small sample size • Poor follow up, non-randomised – selection bias • Retrospective - potential recall bias • Multiple evaluating providers • Ankyloglossia not graded using diagnostic system • Population not treated under same conditions
Ito 2015 ³³	Observational, case series	N = 5 children	1 frenuloplasty under general anaesthetic, 4 frenulotomy without local anaesthetic	Improved articulation in 4 of 5 participants (80%)	<ul style="list-style-type: none"> • Very small sample size • Non-blinded • No control group • Variability in provision of speech therapy • Inhomogeneous sample

N = number of participants

Appendix C. Ankyloglossia Working Group Terms of Reference

Role/Purpose

The role of the Ankyloglossia working group (the working group) is to work with other key bodies to reach a consensus on the management of Ankyloglossia so that the public can access objective and evidence-based advice.

The Ankyloglossia working group sets out to achieve the following:

- Develop a consensus statement regarding ankyloglossia diagnosis and management to assist in ensuring best practice and appropriate referral pathways.
- Formulate consensus statement in combination with advisory panel members regarding diagnosis and management of Ankyloglossia for neonates, infants, children and adults.
- Gain support of key governing bodies.
- Disseminate statement information, including uploading the statement to the Australian Dental Association website.
- Provide accurate facts to educate the general public, in particular new parents, regarding ankyloglossia and its diagnosis and management to allow them to make informed decisions.

1. Term

The Working Group will exist from the first face-to-face meeting and will be ongoing until such time as the objectives listed above have been achieved.

2. Roles and Responsibilities

The Working Group is accountable for:

- Fostering collaboration.
- Removing obstacles to the successful delivery working groups outcomes.
- Maintaining at all times the focus of the working group on the agreed scope, outcomes and benefits.
- Monitoring and managing the factors outside the working group's control that are critical to its success.

The membership of the working group will commit to:

- Attending all meetings and if necessary, nominate a proxy.
- Wholeheartedly championing the working group within and outside of work areas.
- Sharing all communications and information across all working group members.
- Making timely decisions and take timely action so as to not hold up the project.
- Notifying members of the working group, as soon as practical, if any matter arises which may be deemed to affect the development of the consensus statement.

Members of the advisory group will expect:

- That each member will be provided with complete, accurate and meaningful information in a timely manner.
- To be given reasonable time to make key decisions.
- To be alerted to potential risks and issues that could



impact the project, as they arise.

- Open and honest discussions, without resorting to any misleading assertions.
- Ongoing 'health checks' to verify the overall status and 'health' of the working group.

3. Meetings

- All meetings will be chaired by Dr Mihiri Silva
- The first meeting will be held in person.
Any subsequent meetings required to finalise the working group outcomes will be held by teleconference/ videoconference.
- If required subgroup meetings will be arranged outside of these times at a time convenient to subgroup members.
- A meeting quorum will be 50% of the members of the working group.
- Decisions will be made by consensus (i.e. members are satisfied with the decision even though it may not be their first choice).
- Meeting agendas and minutes will be provided by the secretariat, Australian Dental Association, this includes:
 - preparing agendas and supporting papers.
 - preparing meeting notes and information.

4. Amendment, Modification or Variation

This Terms of Reference may be amended, varied or modified in writing after consultation and agreement by working group members.

References

- ¹ Kapoor V, Douglas PS, Hill PS, Walsh LJ, Tennant M. Frenotomy for tongue-tie in Australian children, 2006-2016: an increasing problem. *MJA*. 2018; 208(2):88-89. doi: 10.5694/mja17.00438.
- ² Lisonek M, Liu S, Dzakpasu S, Moore AM, Joseph KS. Changes in the incidence and surgical treatment of ankyloglossia in Canada. *J Paediatr Child Health*. 2017;22(7). 382-386. doi: 10.1093/pch/pxx112.
- ³ Walsh J, Links A, Boss E, Tunkel D. Ankyloglossia and lingual frenectomy: National trends in inpatient diagnosis and management in the United States, 1997-2012. *Otolaryngol Head Neck Surg*. 2017;156(4):735-740. doi: 10.1177/0194599817690135.
- ⁴ World Health Organization [Internet]. *Exclusive breastfeeding for six months best for babies everywhere*. Geneva: World Health Organization; 2011. URL https://www.who.int/mediacentre/news/statements/2011/breastfeeding_20110115/en/. Accessed June 2019.
- ⁵ Baker AR, Carr MM. Surgical treatment of ankyloglossia. *Oper Tech Otolaryngol Head Neck Surg*. 2015;26:28-32.
- ⁶ Adstrum S, Nicholson J. A history of fascia. *Clin Anat*. 2019;32:862-870. doi: 10.1002/ca.23371.
- ⁷ Mills N, Pransky SM, Geddes DT, Mirjalili SA. What is a tongue tie? Defining the anatomy of the in-situ lingual frenulum. *Clin Anat*. 2019;32(6):749-761. doi: 10.1002/ca.23343.
- ⁸ Coryllos E, Genna CW, Salloum AC. Congenital tongue-tie and its impact on breastfeeding. Breastfeeding: Best for mother and baby, *American Academy of Pediatrics Newsletter* [Internet]. 2004. Summer: 1-6.
- ⁹ Martinelli RLC, Marchesan IQ, Berretin-Felix G. Protocol for infants: relationship between anatomic and functional aspects. *Rev CEFAC*. 2013;15(3):599-609.
- ¹⁰ Hazelbaker AK. Tongue-tie: morphogenesis, impact, assessment and treatment. Aidan and Éva Press: Columbus, 2010.
- ¹¹ Schlatter S, Schupp W, Otten JE, Harnisch S, Kunze M, Stravropoulou D et al. The role of tongue-tie in breastfeeding problems – A prospective observational study. *ACTA Paediatr*. 2019;00:1-8.
- ¹² Webb A, Hao W, Hong P. The effect of tongue-tie division on breastfeeding and speech articulation: A systematic review. *Int J Pediatr Otorhinolaryng*. 2013;77:635-646. doi: 10.1016/j.ijporl.2013.03.008.
- ¹³ Razdan R, Callahan S, Saggio R et al. Maxillary Frenulum in Newborns: Association with Breastfeeding. *Otolaryngol Head Neck Surg*. 2020. doi: 10.1177/0194599820913605.
- ¹⁴ Colaway C, Hersh CJ, Baars R, Sally S, Diercks G, Hartnick CJ. Association of feeding evaluation with frenotomy rates in infants with breastfeeding difficulties. *JAMA Otolaryngol Head Neck Surg*. 2019. doi: 10.1001/jamaoto.2019.1696.

- ¹⁵ Huang WJ, Creath CJ. The Midline Diastema: A Review of Its Etiology and Treatment. *Pediatr Dent*. 1995;17(3):171-9.
- ¹⁶ Tracy LF, Gomez G, Overton LJ, McClain WG. Hypovolemic shock after labial and lingual frenulectomy: A report of two cases. *Int J Pediatr Otorhinolaryngol*. 2017;100:223-224. doi: 10.1016/j.ijporl.2017.07.013.
- ¹⁷ Hale M, Mills N, Edmonds L, Dawes P, Dickson N, Barker D et al. Complications following frenotomy for ankyloglossia: A 24-month prospective New Zealand Paediatric Surveillance Unit study. *J Paediatr Child Health*. 2020;56(4):557-562.. doi:10.1111/jpc.14682.
- ¹⁸ Thomas N, Carcillo J. Hypovolemic shock in pediatric patients. *New Horiz*. 1998;6(2):120-129.
- ¹⁹ Dixon B, Gray J, Elliot N, Shand B, Lynn A. A multifaceted programme to reduce the rate of tongue tie release surgery in newborn infants, an observational study. *Int J Ped Otorhinolaryngol*. 2018;113:156-163. doi: 10.1016/j.ijporl.2018.07.045.
- ²⁰ Suter V, Bornstein M. Ankyloglossia: Facts and myths in diagnosis and treatment. *J Periodontol*. 2009;80(8):1204-1219. doi: 10.1902/jop.2009.090086.
- ²¹ Zaghi S, Valcu-Pinkerton S, Jabara M, Norouz-Knutsen L, Govardhan C et al. Lingual frenuloplasty with myofunctional therapy: Exploring safety and efficacy in 348 cases. *LIO*. 2019; 4(5): 489-496. DOI: 10.1002/lio2.297
- ²² Varadan M, Chopra A, Sanghavi AD, Sivaraman K, Gupta K. Etiology and clinical recommendations to manage the complications following lingual frenectomy: a critical review. *J Stomatol Oral Maxillofac Surg*. 2019;120(6);549-553. doi: 10.1016/j.jormas.2019.06.003.
- ²³ Maciag M, Sediva I, Alexander-Scott N. Submandibular swelling and fever following frenulectomy in a 13-day-old infant. *Clin Pediatr*. 2016;55(10):990-992.
- ²⁴ Genther DJ, Skinner ML, Bailey PJ, Capone RB, Byrne PJ. Airway obstruction after lingual frenulectomy in two infants with Pierre-Robin Sequence. *Int J Pediatr Otorhinolaryngol*. 2015;79:1592-1594.
- ²⁵ Isaiah A, Pereira KD. Infected sublingual hematoma: A rare complication of frenulectomy. *Ear Nose Throat J*. 2013;92(7):296-297.
- ²⁶ Opara PI, Gabriel-Job N, Opara KO. Neonates presenting with severe complications of frenotomy: a case series. *J Med Case Rep*. 2012;6(77). doi: 10.1186/1752-1947-6-77
- ²⁷ Ludwig IH, Reiffel RS, Wang FM. Ideal wound healing is not a stretch. *J Pediatr Ophthalmol & Strabismus*. 2018;55(2):82-83. doi: 10.3928/01913913-20180126-01.
- ²⁸ Royal Australasian College of Physicians. Guidelines statement: *Management of procedure-related pain in neonates*.

- ²⁹ O'Shea JE, Foster JP, O'Donnell CPF, Breathnach D, Jacobs SE, Todd DA et al. Frenotomy for tongue-tie in newborn infants. *Cochrane Database of Systematic Reviews*. 2017;3. doi: 10.1002/14651858.CD011065.pub2.
- ³⁰ Salt, H (2019) "Don't snip for speech" *SPA Conference Research Presentation - ahead of publication*
- ³¹ Walls A, Pierce M, Wang H, Steehler A, Steehler M, Harley EH Jr. Parental perception of speech and tongue mobility in three-year olds after neonatal frenotomy. *Int J Pediatr Otorhinolaryngol*. 2014;78:128-31. doi: 10.1016/j.ijporl.2013.11.006.
- ³² Daggumati S, Cohn JE, Brennan MJ, Everts M, McKinnon BJ, Terk AR. Speech and language outcomes in patients with ankyloglossia undergoing frenulectomy: a retrospective pilot study. *OTO Open*. 2019;3(1). doi: 10.1177/2473974X19826943.
- ³³ Ito Y, Shimizu T, Nakamura T, Takatama C. Effectiveness of tongue-tie division for speech disorder in children. *Pediatr Int*. 2015;57:222-6. doi: 10.1111/ped.12474.
- ³⁴ Patel J, Anthonappa RP, King NM. All Tied up! Influences of oral frenulae on breastfeeding and their recommended management strategies. *J Clin Ped Dent*. 2018;42(6):407-415. doi: 10.17796/1053-4625-42.6.1.
- ³⁵ Huang Y, Quo S, Berkowski JA, Guilleminault C. Short lingual frenulum and obstructive sleep apnea in children. *IJPR*. 2015;1(1):1-4.
- ³⁶ Guilleminault C, Huseni S, Lo L. A frequent phenotype for paediatric sleep apnoea: short lingual frenulum. *ERJ open research*. 2016;2(3). DOI: 10.1183/23120541.00043-2016.
- ³⁷ Villa MP, Evangelisti M, Barreto M, Cecili M, Kaditis A. Short lingual frenulum as a risk factor for sleep-disordered breathing in school-age children. *Sleep Med*. 2019;66:119-122. <https://doi.org/10.1016/j.sleep.2019.09.019>.
- ³⁸ Douglas P. Making sense of studies that claim benefits of frenotomy in the absence of classic tongue-tie. *J Human Lact*. 2017;33(3):519-523. doi: 10.1177/0890334417706694.
- ³⁹ Douglas PS, Hiscock H. The unsettled baby: crying out for an integrated, multidisciplinary primary care approach. *MJA*. 2010;193:533-536.
- ⁴⁰ Rosen R, Vandenplas Y, Singendonk M, Cabana M, DiLorenzo C, Gottrand F et al. Pediatric gastroesophageal reflux clinical practice guidelines: joint recommendations of the North American Society for Pediatric Gastroenterology, Hepatology, and Nutrition and the European Society for Pediatric Gastroenterology, Hepatology and Nutrition. *J Pediatr Gastroenterol Nutr*. 2018;66(3):516-554.
- ⁴¹ Kotlow L. Infant gastrointestinal reflux (GER): Benign infant acid reflux or just plain aerophagia? *Int J Child Health Nut*. 2016;5:10-16.

⁴² Kotlow L. Infant reflux and aerophagia associated with the maxillary lip-tie and ankyloglossia (tongue-tie). *Clin Lac*. 2011;2-4;25-29. doi: 10.1891/21580531180711467.

⁴³ Siegel SA. Aerophagia induced reflux in breastfeeding infants with ankyloglossia and shortened maxillary labial frenula (tongue and lip tie). *Int J Clin Pediatr*. 2016;5(1):6-8. doi: <http://dx.doi.org/10.14740/ijcp246w>.

⁴⁴ Hawk C, Minkalis A, Webb C, Hogan O, Vallone S. Manual interventions for musculoskeletal factors in infants with suboptimal breastfeeding: a scoping review. *J Evid Based Integr Med*. 2018;23:1-12. doi: 10.1177/2515690X18816971.

⁴⁵ Holleman AC, Nee J, Knaap S. Chiropractic management of breast-feeding difficulties: a case report. *JCM*. 2011;10(3):199-203. doi: 10.1016/j.jcm.2011.01.010.

⁴⁶ Herzhaft-Le Roy J, Xhignesse M, Gaboury I. Efficacy of osteopathic treatment coupled with lactation consultations for infants' biomechanical sucking difficulties: A randomized control trial. *J Human Lact*. 2017;33(1):165-172.

⁴⁷ Ramoser G, Guóth-Gumberger M, Baumgartner-Sigl S, Zoeggeler T, Scholl-Bürgi S, Karall D. Frenotomy for tongue-tie (frenulum linguae breve) showed improved symptoms in the short- and long-term follow-up. *Acta Paediatrica*. 2019;108:1861-1866.

Signatories for the Ankyloglossia and Oral Frena Consensus Statement

Australasian Academy of Paediatric Dentistry (AAPD)

Australasian Council of Dental Schools (ACDS)

Australian Chiropractic Association (ACA)

Australian College of Midwives (ACM)

Australian Dental and Oral Health Therapists Association (ADOHTA)

Australian and New Zealand Academy of Periodontists (ANZAP)

Dental Hygienists Association of Australia Ltd (DHAA)

Lactation Consultants of Australia and New Zealand (LCANZ)

Osteopathy Australia (OA)

Royal Australasian College of Dental Surgeons (RACDS)

Speech Pathology Australia (SPA)

The Australian and New Zealand Association of Oral and Maxillofacial Surgeons (ANZAOMS)

ada.org.au/ankyloglossia >